E-ISSN 2250-0944
ISSN 2250-1150
doi: 10.31838/ijprt/16.02.965

**Research Article**

# Ultrasonographic Evaluation of Appendiceal Anatomy and its Relationship with Operative Difficulty and Anesthetic Duration During Laparoscopic Appendicectomy

**Tariq Mukhtar Farani[1], Roomana Hashim[2], Saba Akram[3], Mohammad Sohail Anjum Noor[4], Arika Nadeem[5], Noreen Anwar[6*], Madiha Ali[7], Muhammad Imran Aftab[8]**

[1]Head of Surgical Team 1, Department of Surgery, CMH Lahore, Pakistan.
[2]Assistant Professor, Department of Anatomy, Akhtar Saeed Medical and Dental College, Lahore, Pakistan.
[3]Assistant Professor, Department of Anatomy, Baqai Medical University, Karachi, Pakistan.
[4]Assistant Professor, Department of Radiology, Independent Medical College, Faisalabad, Pakistan.
[5]PGR, Department of Diagnostic Radiology, National Hospital, Lahore, Pakistan.
[6*]Associate Professor, Department of Anatomy, Bakhtawar Amin Medical College, Multan, Pakistan.
[7]Professor, Department of Anatomy, Watim Medical & Dental College, Rawat, Rawalpindi, Pakistan.
[8]Professor, Department of Physiology, Watim Medical & Dental College, Rawat, Rawalpindi, Pakistan.

**Corresponding Author:** Noreen Anwar
Associate Professor, Department of Anatomy, Bakhtawar Amin Medical College, Multan, Pakistan.
**Email:** drnoreenanwar@gmail.com

Received: 26.08.26, Revised: 25.10.26, Accepted: 13.11.26

**ABSTRACT**

**Background:** Anatomical variation in the position of the vermiform appendix may significantly influence the technical difficulty of laparoscopic appendicectomy and the duration of anesthesia. Preoperative ultrasonography may help identify these variations and predict operative challenges.

**Objective:** To determine the association between ultrasound-determined appendix position and anatomical variation with operative difficulty and anesthetic duration in patients undergoing laparoscopic appendicectomy.

**Methods:** A prospective observational study was conducted among 120 patients undergoing laparoscopic appendicectomy. Preoperative ultrasonography was used to determine appendix position, categorized as pelvic, retrocecal, subcecal, pre-ileal, and post-ileal. Operative difficulty was assessed using operative duration, difficulty in identification and mobilization of the appendix, requirement for additional port placement, and intraoperative complications. Anesthetic duration was recorded from induction to completion of anesthesia. Statistical analysis was performed using appropriate comparative tests, with $p<0.05$ considered statistically significant.

**Results:** Of the 120 patients, 68 (56.7%) were males and 52 (43.3%) were females, with a mean age of 29.6 ± 11.4 years. The appendix was pelvic in 42 (35.0%), retrocecal in 38 (31.7%), subcecal in 25 (20.8%), pre-ileal in 9 (7.5%), and post-ileal in 6 (5.0%) patients. Mean operative duration was significantly longer in patients with retrocecal and atypically positioned appendices compared with pelvic/subcecal positions (58.4 ± 13.2 vs. 42.7 ± 9.6 minutes; $p<0.001$). Mean anesthetic duration was also significantly greater in the anatomically difficult group (79.6 ± 15.1 vs. 62.3 ± 11.8 minutes; $p<0.001$). Additional port placement was required in 9 (23.7%) patients with retrocecal appendices compared with 3 (3.7%) patients with pelvic/subcecal appendices ($p=0.002$). Difficult appendix identification was reported in 24 (63.2%) retrocecal cases compared with 11 (13.4%) cases with pelvic/subcecal positions ($p<0.001$). Ultrasound-predicted difficult anatomical position demonstrated a significant positive correlation with operative duration ($r=0.61$, $p<0.001$) and anesthetic duration ($r=0.56$, $p<0.001$).

**Conclusion:** Ultrasound-determined appendix position was significantly associated with operative difficulty and anesthetic duration. Retrocecal and other atypical appendix positions were associated with prolonged surgery, increased technical difficulty, and longer anesthesia. Preoperative ultrasonographic assessment may therefore serve as a useful tool for anticipating operative complexity and improving surgical and anesthetic planning in laparoscopic appendicectomy.

**Keywords:** Appendix, acute appendicitis, ultrasonography, anatomical variation, laparoscopic appendicectomy, operative difficulty, anesthetic duration.

## INTRODUCTION

Acute appendicitis is one of the most common causes of acute abdominal pain requiring emergency surgical intervention worldwide. Despite advances in diagnostic imaging, antimicrobial therapy, and minimally invasive surgical techniques, appendicitis continues to represent a substantial burden on emergency surgical services. Laparoscopic appendicectomy has become the preferred operative approach in many healthcare settings because of its advantages, including reduced postoperative pain, shorter hospital stay, faster recovery, and improved cosmetic outcomes. The 2026 World Society of Emergency Surgery (WSES) Jerusalem Guidelines reaffirm laparoscopic appendicectomy as the standard surgical approach for patients requiring operative management of acute appendicitis [1]. Nevertheless, operative complexity varies considerably between patients and may be influenced by disease severity, patient-related factors, surgeon experience, and anatomical variations of the vermiform appendix [2].

The vermiform appendix demonstrates considerable anatomical variability in its position, length, direction, and relationship with adjacent abdominal structures. Commonly described positions include retrocecal, pelvic, subcecal, pre-ileal, and post-ileal, while less frequent variations include subhepatic and paracecal locations. These anatomical differences are clinically important because they may influence the presentation of appendicitis, accessibility of the appendix during surgery, and identification of the appendiceal base. A recent cadaveric investigation by Patra et al. demonstrated that retrocecal positioning was the most frequent anatomical variation (48.9%), followed by pelvic positioning (27.7%), highlighting the considerable variability in appendiceal anatomy [3]. Similarly, anatomical studies conducted in Pakistan have demonstrated variations in appendiceal location, emphasizing the importance of regional anatomical data for clinical and surgical practice [4,5].

Preoperative imaging plays an essential role in the evaluation of patients with suspected acute appendicitis. Ultrasonography is particularly valuable because it is widely available, relatively inexpensive, non-invasive, and does not involve ionizing radiation. It provides information regarding appendiceal diameter, compressibility, wall thickness, periappendiceal inflammatory changes, surrounding fluid collections, and, when adequately visualized, the anatomical position of the appendix. A systematic review and meta-analysis by Arruzza et al. reported pooled sensitivity and specificity of ultrasonography of 82.1% and 85.9%, respectively, for diagnosing acute appendicitis in adults, demonstrating its diagnostic utility while also highlighting its limitations [6]. Comune et al. further emphasized the importance of systematic sonographic assessment, particularly in identifying inflammatory changes and distinguishing uncomplicated from complicated appendicitis. They also highlighted that non-visualization of the appendix does not exclude the diagnosis and may necessitate additional imaging [7]. Current surgical guidelines likewise recognize ultrasonography as a reasonable first-line imaging modality, although computed tomography and magnetic resonance imaging may provide greater diagnostic certainty in selected patients [1,2].

Beyond establishing the diagnosis, preoperative ultrasonography may provide valuable anatomical information that could assist surgeons in anticipating technical difficulties during laparoscopic appendicectomy. A retrocecal appendix, for example, may be concealed behind the cecum, requiring additional mobilization and dissection for adequate visualization. Similarly, pelvic and post-ileal appendices may present challenges because of their relationships with adjacent bowel loops and pelvic structures. Such variations may influence the ease of identification, mobilization, mesoappendix dissection, and ligation of the appendiceal base. A recent study by Cheng et al. (2025) demonstrated that variations in mesoappendiceal orientation were associated with differences in operative duration, additional port requirements, and modifications of the standard surgical approach. Their findings highlight the importance of anatomical configuration in determining the technical complexity of laparoscopic appendicectomy [8].

Operative difficulty is a multifactorial phenomenon that may be reflected by prolonged operative time, difficulty in identifying or mobilizing the appendix, requirement for additional port placement, increased dissection, conversion to open surgery, and intraoperative complications. Cioffi et al., in their multicentre analysis of 485 laparoscopic appendicectomy procedures, identified several factors associated with technically challenging operations and the need for external surgical assistance [9]. Similarly,

Skjold-Ødegaard et al. reported that complicated appendicitis and procedural difficulty were associated with prolonged operating time, with difficult procedures demonstrating a median duration of 90 minutes compared with 59 minutes for non-difficult procedures [10]. These findings suggest that identifying anatomical and pathological factors associated with operative complexity may improve surgical preparedness and facilitate appropriate allocation of operative resources.

The duration of anesthesia is another important perioperative parameter that may be influenced by the technical complexity of laparoscopic appendicectomy. Unlike operative duration, total anesthetic duration includes additional time required for induction, airway management, positioning, maintenance, emergence, and transfer of the patient from the operating theatre. Consequently, technically challenging procedures that require prolonged dissection, additional port placement, or modification of the operative approach may increase total anesthetic exposure. Prolonged anesthesia may have implications for perioperative monitoring, resource utilization, recovery, and postoperative management. Therefore, identifying preoperative anatomical characteristics associated with increased anesthetic duration may be valuable for both surgical and anesthetic planning.

Although recent literature has investigated the diagnostic accuracy of ultrasonography, anatomical variations of the appendix, and factors influencing laparoscopic operative difficulty, the relationship between preoperatively ultrasound-determined appendiceal position, intraoperative technical difficulty, and total anesthetic duration requires further evaluation. In particular, the ability of routine preoperative ultrasonography to anticipate surgically relevant anatomical variations and their potential impact on operative and anesthetic parameters remains an important area of clinical investigation.

Therefore, the present study aims to determine the association between ultrasound-determined appendix position and anatomical variations with operative difficulty and anesthetic duration in patients undergoing laparoscopic appendicectomy. By correlating preoperative ultrasonographic findings with intraoperative observations and perioperative time parameters, this study seeks to evaluate the potential role of ultrasonography as a practical tool for anticipating operative complexity and improving multidisciplinary surgical and anesthetic planning.

## METHODOLOGY

A prospective observational study was conducted on 120 patients diagnosed with acute appendicitis who underwent laparoscopic appendicectomy at the study institution. Patients of either gender, aged 18 years and above, with a clinical and ultrasonographic diagnosis of acute appendicitis and planned for laparoscopic appendicectomy were included. Patients undergoing open appendicectomy, those requiring conversion to open surgery before adequate laparoscopic assessment, patients with a previous history of major abdominal surgery, and cases in which the appendix could not be adequately visualized on preoperative ultrasonography were excluded. Informed consent was obtained from all participants before enrolment, and ethical approval was secured from the institutional review board.

Preoperative ultrasonographic examination was performed by an experienced radiologist using a high-frequency linear transducer, with a curvilinear transducer used when required for deeper visualization. The appendix was assessed for its anatomical location, maximum outer diameter, wall thickness, compressibility and associated periappendiceal inflammatory changes. Based on its anatomical position, the appendix was categorized into five groups: retrocecal, pelvic, subcecal, pre-ileal and post-ileal. The sonographically determined appendiceal position was documented before surgery and subsequently compared with intraoperative findings.

All patients underwent laparoscopic appendicectomy under general anesthesia using a standardized operative approach. Intraoperative assessment included the ease of identification and mobilization of the appendix, presence of inflammatory adhesions, requirement for additional port placement and occurrence of intraoperative complications. Operative difficulty was evaluated using predefined clinical and technical parameters, including difficult identification, difficult mobilization and prolonged operative duration. Operative time was recorded from the initial surgical incision to completion of skin closure, while anesthetic duration was measured from induction of anesthesia to completion of anesthetic care. The operating surgeon and anesthesia team documented the respective

intraoperative and anesthetic parameters using a structured data collection proforma.

Data regarding demographic characteristics, including age and gender, preoperative ultrasonographic findings, intraoperative appendiceal position, operative duration and anesthetic duration were recorded and analyzed. Statistical analysis was performed using IBM SPSS Statistics version 26. Quantitative variables were expressed as mean ± standard deviation, while categorical variables were presented as frequencies and percentages. Differences in operative and anesthetic duration among the different appendiceal positions were assessed using appropriate comparative statistical tests. Associations between anatomical position and categorical indicators of operative difficulty were evaluated using the chi-square test or Fisher's exact test, as appropriate. Pearson's or Spearman's correlation coefficient was used to assess relationships between anatomical difficulty and operative and anesthetic durations, depending on data distribution. A p-value of less than 0.05 was considered statistically significant.

**RESULTS**

Table 1 describes the study population: 120 patients, with 68 males (56.7%) and 52 females (43.3%), and a mean age of 29.6 ± 11.4 years. Table 2 shows where the appendix was located. The pelvic position was most common (35.0%), followed by retrocecal (31.7%), subcecal (20.8%), pre-ileal (7.5%), and post-ileal (5.0%).

Table 3 compares surgical timing between two groups. Patients with retrocecal or atypical appendix positions had longer mean operative times (58.4 vs. 42.7 minutes) and anesthetic times (79.6 vs. 62.3 minutes) than those with pelvic or subcecal positions. Both differences were highly significant ($p < 0.001$).

Table 4 shows that surgical difficulty was greater in the retrocecal group. Additional ports were needed in 23.7% of retrocecal cases compared with 3.7% of pelvic/subcecal cases ($p = 0.002$). Difficult appendix identification occurred in 63.2% of retrocecal cases versus 13.4% of the other group ($p < 0.001$).

Table 5 reports correlations between ultrasound-predicted difficulty and surgical duration. The correlation with operative duration was moderate to strong ($r = 0.61$), and the correlation with anesthetic duration was also positive ($r = 0.56$). Both were statistically significant ($p < 0.001$).

Overall, the findings indicate that retrocecal and atypically positioned appendices make surgery more technically demanding, longer, and more prone to complications such as additional port placement. Ultrasound prediction of difficult anatomy also tracks closely with longer procedures, suggesting it may help surgeons anticipate operative challenges.

Table 1. Patient Demographics and Appendix Position

| Characteristic | Value |
|---|---|
| Total patients | 120 |
| Male | 68 (56.7%) |
| Female | 52 (43.3%) |
| Mean age | 29.6 ± 11.4 years |

Table 2. Distribution of Appendix Position

| Appendix position | n | % |
|---|---|---|
| Pelvic | 42 | 35.0% |
| Retrocecal | 38 | 31.7% |
| Subcecal | 25 | 20.8% |
| Pre-ileal | 9 | 7.5% |
| Post-ileal | 6 | 5.0% |

Table 3. Operative and Anesthetic Duration

| Group | Mean operative time (min) | Mean anesthetic time (min) |
|---|---|---|
| Retrocecal and atypical positions | 58.4 ± 13.2 | 79.6 ± 15.1 |
| Pelvic and subcecal positions | 42.7 ± 9.6 | 62.3 ± 11.8 |
| p-value | $p < 0.001$ | $p < 0.001$ |

Table 4. Surgical Difficulty and Additional Ports

| Outcome | Retrocecal (n = 38) | Pelvic/subcecal | p-value |
|---|---|---|---|
| Additional port placement | 9 (23.7%) | 3 (3.7%) | p = 0.002 |
| Difficult appendix identification | 24 (63.2%) | 11 (13.4%) | p < 0.001 |

Table 5. Correlation Of Ultrasound-Predicted Difficulty with Duration

| Measure | Correlation (r) | p-value |
|---|---|---|
| Operative duration | 0.61 | p < 0.001 |
| Anesthetic duration | 0.56 | p < 0.001 |

Figure 1. Distribution of appendix position among patients (n = 120)

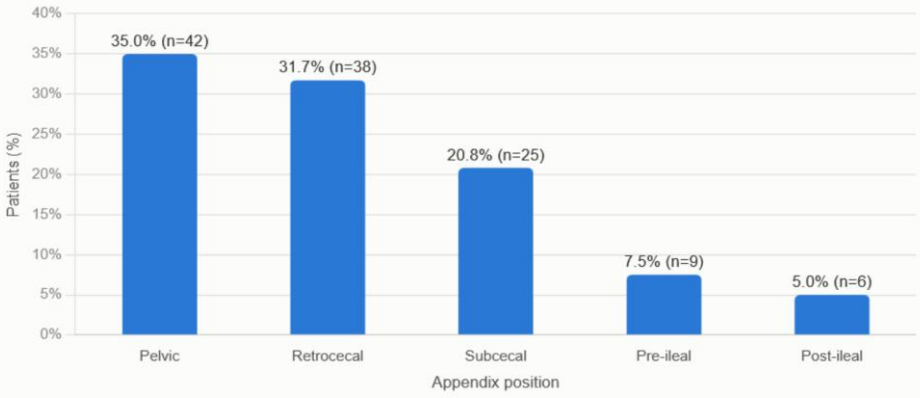


Note: Values are the percentage of patients with each appendix position; n = number of patients.

Figure 2. Distribution of appendix position among patients (n = 120)

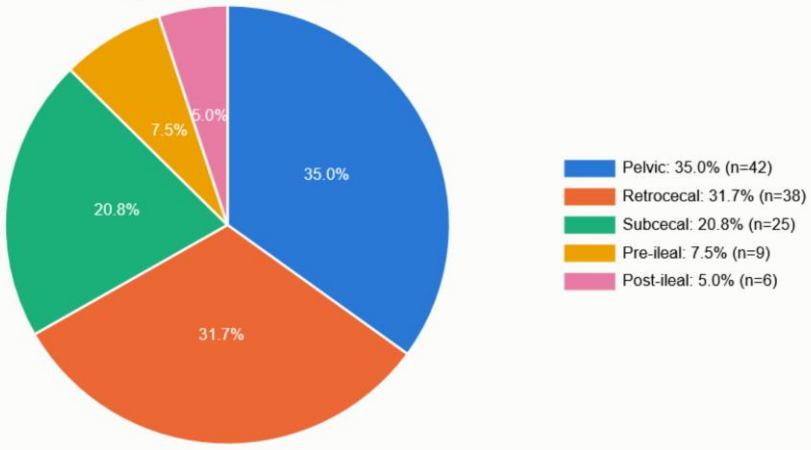


Note: Values are the percentage of patients with each appendix position; n = number of patients.

## DISCUSSION

The present study explored the relationship between preoperative ultrasonographic localization of the vermiform appendix and intraoperative technical challenges during laparoscopic appendicectomy. The findings suggest that appendiceal topography may be an important anatomical determinant of surgical complexity and perioperative anesthetic requirements. In particular, retrocecal positioning was associated with greater difficulty in appendiceal identification and an increased requirement for additional port placement. Furthermore, anatomically challenging appendiceal positions were associated with prolonged operative and anesthetic durations. These observations highlight the potential relevance of preoperative anatomical assessment in anticipating procedural complexity and facilitating individualized surgical planning.

The distribution of appendiceal positions observed in this study reflects the considerable anatomical variability of the vermiform appendix. Pelvic and retrocecal positions represented the predominant anatomical configurations, although substantial variation was also observed in the remaining categories. Differences in the reported distribution of appendiceal positions across anatomical and clinical studies may be attributable to population characteristics, methodological differences, classification systems and the techniques used for anatomical identification. Byateppanavar et al. reported a predominance of retrocecal positioning in their investigation correlating clinical examination, ultrasonographic findings and intraoperative observations [11]. Such variations emphasize that appendiceal topography should be assessed individually rather than inferred from conventional anatomical descriptions.

Ultrasonography provides a potentially valuable means of evaluating appendiceal anatomy before surgical intervention. In addition to identifying inflammatory changes, systematic sonographic examination may facilitate localization of the appendix and assessment of its relationship with adjacent structures. However, successful visualization is influenced by several factors, including patient body habitus, bowel gas, inflammatory changes, anatomical depth and operator expertise. Pfeifer et al. demonstrated that structured coaching and targeted educational interventions can improve sonographic visualization of the appendix [12]. Similarly, Chui et al. reported improved appendiceal visualization following the implementation of a structured quality-improvement approach [13]. These observations reinforce the importance of standardized scanning protocols and appropriate radiological expertise when using ultrasonography for anatomical localization. The diagnostic value of sonographic localization should therefore be interpreted in the context of image quality and the reliability of anatomical identification.

An important observation in the present study was the association between retrocecal positioning and difficulty in intraoperative identification of the appendix. This relationship has a plausible anatomical basis. A retrocecal appendix may remain partially concealed behind the cecum or ascending colon, limiting direct visualization during initial laparoscopic exploration. Inflammatory adhesions and surrounding tissue edema may further obscure the appendiceal outline and complicate dissection. Conversely, pelvic and subcecal appendices may offer relatively direct access in selected patients, although their proximity to the terminal ileum, pelvic structures and adjacent bowel loops may introduce different technical challenges. Byateppanavar et al. also demonstrated differences in the identification of appendiceal positions through ultrasonographic and intraoperative assessment, supporting the clinical relevance of anatomical localization [11]. These findings suggest that the technical implications of appendiceal position are determined not simply by its anatomical classification but also by its spatial relationship with neighbouring structures and the surrounding inflammatory process.

The association between anatomical position and operative duration further supports the contribution of appendiceal topography to procedural complexity. Retrocecal and other challenging positions may require additional operative maneuvers, including cecal mobilization, retraction, adhesiolysis and modification of the dissection plane. Such maneuvers may increase the time required to achieve adequate visualization and safely isolate the appendiceal base. Skjold-Ødegaard et al. demonstrated that laparoscopic appendicectomy performance and operative duration are influenced by procedural difficulty and surgical training-related factors [14]. Their observations emphasize that operative time is a composite outcome reflecting anatomical complexity, disease severity and technical proficiency. Therefore, the prolonged operative duration observed in anatomically challenging cases should not be attributed exclusively to appendiceal position without considering these additional determinants.

The requirement for additional port placement provides another clinically relevant indicator of operative complexity. Additional access may become necessary when conventional port positioning does not provide sufficient exposure, traction or instrument triangulation. In retrocecal appendices, limited visualization may necessitate alternative approaches to retraction and mobilization of the cecum. Cheng et al. investigated variations in mesoappendiceal orientation and demonstrated that anatomical configuration may influence operative strategy, dissection requirements and the need for additional port placement [15]. Their findings complement the present observations by illustrating how

anatomical variation can affect intraoperative decision-making. Nevertheless, additional port placement should be regarded as an adaptive surgical response rather than an independent indicator of poor operative performance, as it may facilitate safer dissection and prevent unnecessary tissue manipulation.

An additional finding of clinical relevance was the association between anatomical difficulty and anesthetic duration. Anesthetic exposure is influenced by the overall duration and complexity of the surgical procedure, together with induction, airway management, maintenance and emergence. Technically demanding appendicectomies may require prolonged anesthetic care because of additional dissection, difficult mobilization and modifications in the operative approach. Although anesthetic duration is closely related to operative time, the two parameters represent distinct perioperative measurements. Their simultaneous evaluation provides a broader perspective on the implications of anatomical variation for operating theatre utilization and perioperative management. Uttinger et al. examined the relationship between surgical timing and outcomes in adult patients with acute appendicitis, highlighting the importance of perioperative factors in the management of this condition [16]. However, the specific contribution of appendiceal position to anesthetic duration remains insufficiently characterized, making this aspect of the present investigation particularly relevant.

The observed positive correlations between anatomical difficulty and both operative and anesthetic duration further support the relationship between appendiceal topography and perioperative complexity. Anatomical configurations that impede visualization and mobilization may increase the technical demands of surgery, consequently extending the duration of operative and anesthetic care. Nevertheless, correlation should not be interpreted as evidence of an independent causal relationship. Other factors, including inflammatory severity, perforation, adhesions, obesity and surgeon experience, may influence both operative difficulty and procedural duration. Sadaf et al. described the contribution of complicated inflammatory pathology, adhesions and inadequate visualization to operative challenges and conversion during laparoscopic appendicectomy [17]. These findings indicate that anatomical position should be considered alongside pathological and patient-related characteristics when evaluating surgical complexity.

From a clinical perspective, preoperative recognition of potentially challenging appendiceal positions may improve operative preparedness. Communication of relevant anatomical findings between the radiologist and operating surgeon may facilitate anticipation of technical difficulties, selection of appropriate port configurations and preparation for possible modifications in surgical technique. Such information may also assist anesthetic teams in anticipating potentially prolonged procedures and planning perioperative resources. Patel et al. highlighted the importance of considering disease characteristics and operative approach when evaluating outcomes following appendicectomy [18]. In this context, anatomical localization may represent an additional component of individualized perioperative assessment rather than a replacement for established clinical and radiological evaluation.

The present study has several strengths. The integration of preoperative ultrasonographic assessment with intraoperative observations provides a clinically oriented evaluation of appendiceal anatomy. Furthermore, the simultaneous consideration of technical difficulty, operative duration, additional port requirements and anesthetic duration offers a broader assessment of the perioperative implications of anatomical variation. Nevertheless, certain limitations should be acknowledged. The single-centre design and relatively limited sample size may restrict the generalizability of the findings. Ultrasonographic localization may be affected by operator expertise, bowel gas, patient body habitus and inflammatory changes. Additionally, operative complexity is influenced by multiple factors that may not be fully explained by appendiceal position alone. Potential confounders, including body mass index, severity of appendicitis, perforation, adhesions and surgeon experience, should be considered. The absence of multivariable analysis also limits the ability to establish whether appendiceal position independently contributes to operative and anesthetic duration. Future multicentre prospective studies incorporating standardized sonographic protocols, intraoperative anatomical confirmation and validated operative difficulty scores are warranted.

**Strengths and Limitations**

An important strength of the present study is its integration of preoperative ultrasonographic findings with intraoperative observations and anesthetic parameters. Rather than limiting the assessment to the diagnostic accuracy of ultrasound, the study explores its potential contribution to anticipating surgical complexity and perioperative requirements. The inclusion of different anatomical positions and multiple indicators of operative difficulty provides a broader assessment of the clinical relevance of appendiceal localization.

However, several limitations should be acknowledged. First, the relatively small sample size and single-centre setting may limit the generalizability of the findings. Second, ultrasonographic identification of appendiceal position may be influenced by operator expertise, patient body habitus and surrounding inflammatory changes. Third, operative difficulty may be affected by factors other than anatomical position, including the severity of inflammation, adhesions, perforation, obesity and surgeon experience. These potential confounders should be considered when interpreting the observed associations. Furthermore, the study did not establish whether ultrasonographic localization independently predicts operative difficulty after adjustment for these factors. Larger multicentre studies incorporating standardized operative difficulty scores and multivariable statistical analysis are recommended to validate these observations.

## CONCLUSION

The findings of this study suggest that preoperative ultrasonographic localization of the vermiform appendix may provide clinically relevant information regarding the technical complexity of laparoscopic appendicectomy. Retrocecal and other anatomically challenging positions were associated with greater difficulty in appendiceal identification, increased requirements for additional port placement and prolonged operative and anesthetic durations. The positive correlations between anatomical difficulty and perioperative parameters further support the potential importance of appendiceal topography in surgical planning. Incorporating systematic anatomical assessment into routine preoperative ultrasonography may improve communication between radiologists, surgeons and anesthetists and facilitate better operative preparedness. Further multicentre investigations are required to establish the independent predictive value of sonographic appendiceal localization.

## REFERENCES

1. Podda M, Ceresoli M, De Simone B, et al. Diagnosis and treatment of acute appendicitis: 2025 edition of the World Society of Emergency Surgery Jerusalem Guidelines. JAMA Surg. 2026;161(3):283-295. doi:10.1001/jamasurg.2025.6218.
2. Kumar SS, Collings AT, Lamm R, et al. SAGES guideline for the diagnosis and treatment of appendicitis. Surg Endosc. 2024;38(6):2974-2994. doi:10.1007/s00464-024-10813-y.
3. Patra A, Kaur H, Chhabra U, Sghar A, Balawender K, Pasternak A, et al. Reappraisal of the variational anatomy of the vermiform appendix and their possible clinical applicability: a cadaveric analysis. Folia Morphol (Warsz). 2024;83(3):716-726. doi:10.5603/fm.96443.
4. Yousaf M, Kanwal S, Ali AN, Ali A, Ahmad N, Ghafoor A. Variation in anatomical position of vermiform appendix. Pak J Med Health Sci. 2023;17(3):649. doi:10.53350/pjmhs2023173649.
5. Sarma M, Dutta M, Doley A. Different positions of vermiform appendix in human cadavers: a cross-sectional study. J Clin Diagn Res. 2022;11(3):AO29-AO32. doi:10.7860/JCDR/2022/52087.2809.
6. Arruzza E, Milanese S, Li LSK, Dizon J. Diagnostic accuracy of computed tomography and ultrasound for the diagnosis of acute appendicitis: a systematic review and meta-analysis. Radiography (Lond). 2022;28(4):1127-1141. doi:10.1016/j.radi.2022.08.012.
7. Comune R, Tamburrini S, Durante A, Bonito G, Ferrari R, Galluzzo M, et al. Ultrasonography (US) examination of acute appendicitis (AA): diagnosis of complicated and uncomplicated forms and when US is not enough. J Med Imaging Interv Radiol. 2024;11:14. doi:10.1007/s44326-024-00002-5.
8. Bekki T, Abe T, Namba Y, Okimoto S, Mukai S, Saito Y, Oishi K, Fujisaki S, Ohdan H, Fukuda T. Validation of appendiceal stump invagination in laparoscopic appendectomy. Asian journal of endoscopic surgery. 2023 Apr;16(2):203-9..
9. Cioffi SPB, Spota A, Altomare M, Granieri S, Bini R, Virdis F, et al. Factors influencing the difficulty and need for external help during laparoscopic

appendectomy: analysis of 485 procedures from the Resident-1 multicentre trial. J Pers Med. 2022;12(11):1904. doi:10.3390/jpm12111904.
10. Sirimanna P, Ravindran P, Smigielski M, Gladman MA, Naganathan V. Validation and reliability testing of a rating scale for objective assessment of performance in laparoscopic appendicectomy surgery. ANZ Journal of Surgery. 2022 Jul;92(7-8):1731-6.
11. Byateppanavar RV, Teggimani VK, Pratheeksha HP, Chalmal MAAR. A study to correlate different anatomical positions of the appendix by clinical examination, USG findings with intra-operative findings and sequelae associated with respect to it in KIMS, Hubli. Res J Med Sci. 2024;18(9):294-303. https://doi.org/10.36478/makrjms.2024.9.294.303.
12. Pfeifer CM, Carrejo B, Lewis S, Hutchinson K, Gokli A, Kwon J. Structured coaching as a means to improve sonographic visualization of the appendix: a quality improvement initiative. Emerg Radiol. 2023;30(2):161-166. https://doi.org/10.1007/s10140-022-02106-5.
13. Chui S, Phinney C, Hansen K, Danskin D. Improving sonographic visualisation of the appendix in a regional referral hospital. BMJ Open Qual. 2025;14(1):e002865. https://doi.org/10.1136/bmjoq-2024-002865.
14. Skjold-Ødegaard B, Ersdal HL, Assmus J, Søreide K, et al. Internal and external factors affecting the performance score of surgical trainees doing laparoscopic appendectomy: a prospective, observational cohort study in a structured training programme. Surg Endosc. 2024;38:4939-4946. https://doi.org/10.1007/s00464-024-11007-2.
15. Cheng E, Shamavonian R, Mui J, Bunjo Z, Matar A, Barnard J, et al. Mesoappendix position variations in laparoscopic appendicectomy; a new anatomical classification to guide surgical strategy. Updates Surg. 2025;77(3):835-842. https://doi.org/10.1007/s13304-025-02172-7.
16. Uttinger K, Baum P, Diers J, Seehofer D, Germer CT, Wiegering A. The impact of surgical timing on outcome in acute appendicitis in adults: a retrospective observational population-based cohort study. Int J Surg. 2024;110(8):4850-4858. https://doi.org/10.1097/JS9.0000000000001528.
17. Sadaf F, Asif M, Iqbal A, Fatima P, Younas A, Mushtaq J, et al. Conversion rates and outcomes of laparoscopic appendectomy in complicated appendicitis: a retrospective study. Cureus. 2025;17(8):e90411. https://doi.org/10.7759/cureus.90411.
18. Patel PY, Rathod R, Akhani MK. Laparoscopic versus open appendectomy in complicated and uncomplicated appendicitis in adults: a two-year single-center retrospective cohort study. Cureus. 2025;17(9):e92258. https://doi.org/10.7759/cureus.92258.